

Luis A. Sanchez, M.D.
Chief Medical Examiner



Main: (713) 796-9292
Fax: (713) 796-6844


Harris County Institute of Forensic Sciences

STATE OF TEXAS §
 §
COUNTY OF HARRIS §

I, Luis A. Sanchez, M.D., Chief Medical Examiner of Harris County, do hereby certify that the attached autopsy report and toxicology report (where applicable) represent a true and correct copy of the Autopsy/External Examination findings on the body of

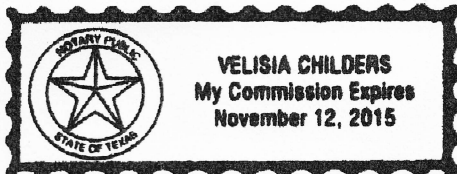
Marcell Lee Taylor, Case # Case 88-6084.

Witness my hand in Harris County, Texas, this 14th day of May, 2012.



Chief Medical Examiner
Harris County, Texas

Subscribed and sworn to before me this 14th day of May, 2012.





Notary Public, Harris County, Texas



JOSEPH A. JACHIMCZYK, M.D., J.D.

FORENSIC PATHOLOGIST
ATTORNEY AT LAW
CHIEF MEDICAL EXAMINER



(713) 796-9292
(713) 796-6815



OFFICE OF THE MEDICAL EXAMINER OF HARRIS COUNTY
JOSEPH A. JACHIMCZYK FORENSIC CENTER
1885 OLD SPANISH TRAIL
HOUSTON, TEXAS 77054

AUTOPSY REPORT

Case 88 - 6084

September 27, 1988

PATHOLOGICAL DIAGNOSES ON THE BODY


OF


Marcell Lee Taylor
2607 Riverside, #5
Houston, Texas

1. Stab wound of the neck, through and through.
2. Stab wound of the chest, through and through.
3. Cutting wound of the chest.
4. Cutting wound of the left arm.

OPINION

It is our opinion that the decedent, Marcell lee Taylor, came to his death as a result of stab wound of the neck, through and through, Homicide.


Joseph A. Jachimczyk, M.D., J.D.
Chief Medical Examiner


Vladimir M. Parungao, M.D.
Assistant Medical Examiner

POSTMORTEM EXAMINATION ON THE BODY OF

Marcell Lee Taylor
2607 Riverside, #5
Houston, Texas

HISTORY: This 3 year old black male child was found dead at 11:38 p.m., on September 26, 1988, at 2475 South Kirkwood. (See Companion Case 88 - 6085).

AUTOPSY: The autopsy was performed in the Joseph A. Jachimczyk Forensic Center of Harris County by Assistant Medical Examiner Vladimir M. Parungao, M.D., at the request of Chief Medical Examiner Joseph A. Jachimczyk, M.D., J.D., beginning at 8:45 a.m., on September 27, 1988.

EXTERNAL APPEARANCE: The body was that of a 3 year old black male child, appearing to be the stated age, measuring 41 inches in length and weighing 39 pounds. The body was well developed and well nourished in appearance. There was total body rigidity and fixed postmortem lividity posteriorly. The head was normocephalic with a normal amount of kinky black hair, measuring 1-1/2 inches in length. The eyes were covered with corneal caps. The ears and nose were unremarkable. The mouth contained natural baby teeth. There was a stab wound of exit on the left side of the back of the head. The neck was symmetrical and stable. There was a stab wound of entrance on the left side at the left submandibular area. The thorax was symmetrical in shape and contour. There was a stab wound of entrance on the left side. There was a cutting wound on the left upper side, measuring 1 inch in length and gaping up to 5/16 inch in width. There were abrasions on the side of this cutting wound. There were also abrasions on the side of the stab wound previously described. There was a linear abrasion on the left upper side of the chest, measuring 1 inch in length. There was a tiny abrasion on the midupper side of the chest, measuring 1/8 inch in diameter. The abdomen was flat. The external genitalia were those of a normal circumcised male child with unremarkable testes in the scrotum. The lower extremities showed no deformity. The upper extremities showed a small cutting wound on the left arm, measuring 1/4 inch in length by 3/16 inch in width. There were no deformities noted. The back showed a stab wound of exit on the left side. The cerebrospinal fluid was clear.

INTERNAL EXAMINATION: Section: The body was opened through the usual Y-shaped thoracoabdominal incision. There was a normal amount of subcutaneous fat and muscle tissue encountered upon dissection that measured 5/16 inch at the level of the umbilicus. The stab wound on the left side of the chest never entered the thoracic cavity. The cutting wound on the left side of the chest only

involved the soft tissues and muscles without entering the thoracic cavity. After removal of the sternal plate, there was no increase in fluid or adhesions in either pleural cavity. The pericardial sac was smooth and glistening and upon opening, there was no increase in fluid or adhesions. The abdominal cavity contained no increase in fluid or adhesions. There was no organ displacement noted. The diaphragmatic domes were normally situated and the appendix was present in the right lower quadrant.

HEART: The heart weighed 100 grams. The epicardial surface was smooth and glistening. The epicardial fat was normal in amount and distribution. On section, the right ventricle averaged 1/8 inch in thickness and the left ventricle averaged 5/16 inch in thickness. The myocardium was beefy red in appearance. The endocardium, papillary muscles, chordae tendineae, the valves and their cusps, the foramen ovale, the coronary vessels and the aorta were all grossly unremarkable on section.

THYMUS: The thymus weighed 50 grams. It had a normal bilobate configuration. The cut surfaces showed normal appearing, pink-tan, lobulated, lymphoid tissue.

LUNGS: The right lung weighed 150 grams and the left lung weighed 120 grams. The pleurae were smooth and glistening. The fissures were well demarcated. On section, the parenchyma was grossly unremarkable. Examination of the tracheobronchial tree showed a small amount of mucoid secretions. Examination of the pulmonary vessels showed no evidence of thrombi or emboli.

LIVER: The liver weighed 450 grams. The capsule was smooth and glistening. On section, the parenchyma was orange-brown in appearance. The gallbladder contained 20 milliliters of bile and appeared grossly unremarkable as was the biliary tree.

Pancreas: The pancreas was normal in shape and configuration and on section, it was grossly unremarkable.

Adrenals: The adrenal glands were unremarkable, bilaterally.

SPLEEN: The spleen weighed 75 grams. The capsule was smooth and glistening. On section, the parenchyma was grossly unremarkable.

GENITOURINARY TRACT: The kidneys together weighed 100 grams. The capsules were thin, easily stripped, exposing a smooth surface. On section, the corticomedullary junctions were well demarcated. The calyces, pelves, ureters, urinary bladder, prostate and testes were grossly unremarkable on section.

GASTROINTESTINAL TRACT: The stomach was normal in shape and configuration. The serosal surfaces, muscularis layer and mucosa were grossly unremarkable. The lumen was empty. The duodenum and the rest of the small and large intestines including the appendix and esophagus were grossly unremarkable.

BONES: There was a stab wound track involving the left scapula.

NECK: There was soft tissue hemorrhage surrounding the stab wound track on the left submandibular area. There were cutting wounds involving the left common carotid artery and the left jugular vein surrounded with hemorrhage. The thyroid gland, larynx, vocal cords, epiglottis, hyoid bone and tongue were grossly unremarkable on section.

HEAD: The scalp was incised and reflected. There was subgaleal hemorrhage surrounding the stab wound track involving the back of the head. The calvarium was intact. There was no subdural, epidural or subarachnoid hemorrhage. The meninges were smooth and glistening. The gyri and sulci were unremarkable. The cerebral hemispheres were symmetrical in shape and contour and the brain weighed 1280 grams. On section, the gray and white matter were well demarcated. The ventricular system, including the choroid plexus, was grossly unremarkable. The cerebellum and the midbrain were grossly unremarkable on section.

DESCRIPTION OF INJURIES: There was a stab wound in the left side of the neck at the left submandibular area located 1-1/2 inches to the left of midline and 7 inches below the top of the head. The wound measured 1 inch in length and gaped up to 1/8 inch in width. There was no blunt end. The stab wound track perforated the soft tissues and muscles of the left side of the neck, perforated the left common carotid artery, the left jugular vein and exited on the left side of the head at a point 2 inches to the left of midline and 4 inches below the top of the head. The exit wound measured 9/16 inch in length and gaped up to 3/16 inch in width. This was located 4 inches from the entrance wound. The direction of the stab wound was from front to back, upwards and slightly to the left.

There was a stab wound to the left side of the chest located 2-1/2 inches to the left of midline, 3 inches below the suprasternal notch and 12 inches below the top of the head. The wound measured 1 inch in length and gaped up to 3/16 inch in width. There was no blunt end. The stab wound track perforated the soft tissues and muscles of the left side of the chest, did not enter the thoracic cavity, perforated the scapula and exited on the left side of the back at a point 4 inches to the left of midline and 10 inches below the top of the head. The exit wound measured 7/16 inch in length. The direction of the stab wound was from front to back, upwards and

Marcell Lee Taylor

Case 88 - 6084

-5-

towards the left. There was no vital structure penetrated by this stab wound. The exit wound was 4 inches from the entrance wound.

INVESTIGATOR'S REPORT

(X)AUTOPSY
()VIEW
()INQUEST ONLY

Investigator: James Ebdon

Case No. 88 - 6084

Decedent: Marcell lee Taylor Race: B Sex: M Age: 3 D.O.B.: 4/4/1985

Home Address: 2607 Riverside, #5, Houston, Texas Telephone: None

Date of Death: September 26, 1988 Time: 11:38 p.m. Found: Yes

Place of Death: 2475 South Kirkwood, Houston, Texas City(X)/County()/Pet()
Telephone: 496-4490

Zip Code: 77077

M.E. Notified: James Ebdon Date: September 26, 1988 Time: 11:45 p.m.

Place of Inquest: 2475 South Kirkwood, Houston, Texas Date: September 27, 1988

Informant: Houston Police Department, Officer V. L. Cook, Unit 20G40 Time: 12:10 a.m.

Next of Kin: Sharon Brown (mother) Address: 2607 Riverside, #5, Houston, Texas

Next of Kin Notified by: Homicide Detective P. C. Bloid Date: 9/17/1988 Time: 6:45 a.m.

Telephone: None

Personal Physician:

Address:

Telephone:

Location, Position, and Surroundings of Body: The decedent was lying on his back on the ground on a pathway 100 feet northeast of the back of the concrete driveway of Fudrucker's Restaurant.

Clothing: The clothing consisted of pants, shirt, and shoes.

Information: According to Officer Cook, the decedent was found dead at 11:38 p.m, on September 26, 1988 by Jaime Hunter, who came across the decedent and his cousin, Shandra Charles (Companion Case 88-6085). Both had been attacked by an unknown suspect who stabbed them and attempted to rape Ms. Charles. At 6:30 a.m., on September 26, 1988 Homicide Detective P. C. Bloid, Unit 1475, identified this decedent with his mother. The suspect, Preston Hughes, was being held at this time and charges are pending.

M.E. Photos: (X)Yes ()No Police Agency: Houston Police Department
Property: There was no property involved.

Case No.: 78815888

Funeral Home Transporting Decedent: Boyd Smith Funeral Home, Houston, Texas ()Requested

Funeral Home Receiving Decedent: Johnson Funeral Home, Houston, Texas. (X)Dispatched