

## CERTIFICATE OF DEATH

STATE OF CALIFORNIA - DEPARTMENT OF PUBLIC HEALTH

7097-034671

DEATH FILE NUMBER

LOCAL JURISDICTION DISTRICT AND COUNTY HEALTH DEPARTMENT

DECEDENT PERSONAL DATA	1a. NAME OF DECEASED—FIRST NAME <b>THOMAS</b>		1b. MIDDLE NAME <b>JAY</b>		1c. LAST NAME <b>SEBRING</b> AKA <b>MURPHY</b>		2a. DATE OF DEATH—MONTH DAY YEAR <b>August 9, 1969</b>		2b. TIME <b>10:10 A.M.</b>			
	3. SEX <b>Male</b>	4. COLOR OR RACE <b>Caucasian</b>	5. BIRTHPLACE <b>Alabama</b>		6. DATE OF BIRTH <b>October 10, 1933</b>		7. AGE <b>35</b> YEARS	8. MARRIED <input type="checkbox"/> YES <input checked="" type="checkbox"/> NO		9. SOCIAL SECURITY NUMBER <b>386-32-4178</b>		
	8. NAME AND BIRTHPLACE OF FATHER <b>Bernard J. Kurner-Michigan</b>				9. MOTHER NAME AND BIRTHPLACE OF MOTHER <b>Margarette E. Gibb-Alabama</b>				12. NAME OF SURVIVING SPOUSE (IF DECEASED, GIVE SPOUSE NAME) <b>Divorced</b>			
	10. CITIZEN OF WHAT COUNTRY <b>U.S.A.</b>		11. SOCIAL SECURITY NUMBER <b>386-32-4178</b>		12. MARRIED, NEVER MARRIED, DIVORCED, SPOUSES SEPARATE <b>Divorced</b>		13. NAME OF SURVIVING SPOUSE (IF DECEASED, GIVE SPOUSE NAME) <b>-</b>		14. LAST OCCUPATION <b>President and Chairman of Board</b>			
PLACE OF DEATH	15. PLACE OF DEATH—NAME OF HOSPITAL OR OTHER IN-PATIENT FACILITY		16a. STREET ADDRESS—STREET AND NUMBER, OR LOCATION		16b. CITY OR TOWN		16c. COUNTY		16d. STATE		17. KIND OF INDUSTRY OR BUSINESS <b>Hair Cosmetics &amp; Grooming Products for Men</b>	
	18a. CITY OR TOWN <b>Los Angeles</b>		18b. COUNTY <b>Los Angeles</b>		18c. STATE <b>California</b>		19. MONTH OF DEATH IN COUNTY OF DEATH <b>11</b> YEARS		19a. LENGTH OF DEATH IN CALIFORNIA <b>11</b> YEARS		19b. INSIDE CITY CORPORATE LIMITS (SPECIFY YES OR NO) <b>yes</b>	
	19a. USUAL RESIDENCE—STREET ADDRESS (STREET AND NUMBER OR LOCATION) <b>9810 Easton Drive</b>		19b. CITY OR TOWN <b>Los Angeles</b>		19c. COUNTY <b>Los Angeles</b>		19d. STATE <b>California</b>		20. NAME AND MAILING ADDRESS OF INFORMANT <b>John E. Madden-friend 725 North Fairfax Avenue Los Angeles, California</b>			
PHYSICIAN'S OR CORONER'S CERTIFICATION	21a. CORONER. I HEREBY CERTIFY THAT DEATH OCCURRED AT THE PLACE SHOWN ABOVE FROM THE CAUSES SHOWN BELOW AND THAT I HAVE HELD ON THE REMAINS OF DECEASED AS REQUIRED BY LAW		21b. PHYSICIAN. I HEREBY CERTIFY THAT I HAVE EXAMINED THE BODY AND PLACE SHOWN ABOVE FROM THE CAUSES SHOWN BELOW AND THAT I APPROVED THE DECEASED		21c. PHYSICIAN OR CORONER. SIGNATURE AND TITLE AS FOLLOWS <i>John A. ...</i> <b>Coroner</b>		21d. DATE SIGNED <b>8-12-69</b>		21e. SIGNATURE OF LOCAL REGISTRAR <i>Richard ...</i>		21f. LICENSE NUMBER <b>4753</b>	
	22a. CORONER'S CERTIFICATION <b>Investigation</b>		22b. DATE SHIPPED <b>8-13-69</b>		22c. NAME OF CEMETERY OR CREMATORY <b>Holy Sepulchre Cemetery Southfield, Mich.</b>		22d. LOCAL REGISTRAR SIGNATURE <i>Richard ...</i>		22e. LICENSE NUMBER <b>4753</b>		22f. DATE OF DEATH <b>AUG 13 1969</b>	
FUNERAL DIRECTOR AND LOCAL REGISTRAR	22a. SPECIFY BURIAL, ENTOMBMENT OR CREMATION <b>BURIAL</b>		22b. DATE SHIPPED <b>8-13-69</b>		22c. NAME OF CEMETERY OR CREMATORY <b>Holy Sepulchre Cemetery Southfield, Mich.</b>		22d. LOCAL REGISTRAR SIGNATURE <i>Richard ...</i>		22e. LICENSE NUMBER <b>4753</b>		22f. DATE OF DEATH <b>AUG 13 1969</b>	
	23. NAME OF FUNERAL DIRECTOR (OR PERSON ACTING AS SUCH) <b>FOREST LAWN MEMORIAL-PARK AMBROSIO, CALIFORNIA</b>		24. DATE SHIPPED <b>8-13-69</b>		24. NAME OF CEMETERY OR CREMATORY <b>Holy Sepulchre Cemetery Southfield, Mich.</b>		24. LOCAL REGISTRAR SIGNATURE <i>Richard ...</i>		24. LICENSE NUMBER <b>4753</b>		24. DATE OF DEATH <b>AUG 13 1969</b>	
MEDICAL AND HEALTH DATA	25. PART I. DEATH WAS CAUSED BY: IMMEDIATE CAUSE <b>EXSANGUINATION</b>											
	CONDITIONS OF ANY, WHICH GAVE RISE TO THE IMMEDIATE CAUSE (A), STATING THE UNDERLYING CAUSE LAST. (A) <b>EXSANGUINATION</b> (B) <b>MULTIPLE STAB WOUNDS</b> (C)											
	26. PART II. OTHER SIGNIFICANT CONDITIONS—CONTRIBUTING TO DEATH BUT NOT RELATED TO THE IMMEDIATE CAUSE SHOWN IN PART I.											
INJURY INFORMATION	33. SPECIFY ACCIDENT, SUICIDE OR HOMICIDE		34. PLACE OF INJURY (SPECIFY HOME, FACTORY, OFFICE BUILDING, ETC.)		35. INJURY AT WORK (SPECIFY YES OR NO)		36a. DATE OF INJURY—MONTH DAY YEAR		36b. HOUR			
	37a. PLACE OF INJURY (STREET AND NUMBER OR LOCATION AND CITY OR TOWN)		37b. DISTANCE FROM PLACE OF INJURY TO HOSPITAL (SPECIFY YES OR NO)		37c. WITH LABORATORY TESTS DONE FOR DRUGS OR TOXIC CHEMICALS (SPECIFY YES OR NO)		37d. WITH LABORATORY TESTS DONE FOR ALCOHOL (SPECIFY YES OR NO)		37e. WITH LABORATORY TESTS DONE FOR OTHER CAUSES OF DEATH (SPECIFY YES OR NO)			
	38. WITH LABORATORY TESTS DONE FOR DRUGS OR TOXIC CHEMICALS (SPECIFY YES OR NO) <b>Yes</b>		38. WITH LABORATORY TESTS DONE FOR ALCOHOL (SPECIFY YES OR NO) <b>Yes</b>		38. WITH LABORATORY TESTS DONE FOR OTHER CAUSES OF DEATH (SPECIFY YES OR NO) <b>Yes</b>		38. WITH LABORATORY TESTS DONE FOR OTHER CAUSES OF DEATH (SPECIFY YES OR NO) <b>Yes</b>		38. WITH LABORATORY TESTS DONE FOR OTHER CAUSES OF DEATH (SPECIFY YES OR NO) <b>Yes</b>			
40. DESCRIBE HOW INJURY OCCURRED (ENTER NATURE OF EVENTS WHICH RESULTED IN INJURY; NATURE OF INJURY SHOULD BE ENTERED IN PART II.)												
STATE REGISTRAR	A	B	C	D	E	F	2611					

File # 69 8795

## OFFICE OF CHIEF MEDICAL EXAMINER-CORONER

Date AUGUST 10, 1969 Time 2:15 p. m.

I performed an autopsy on the body of JAY SEBRING  
 at OFFICE OF CHIEF MEDICAL EXAMINER-CORONER, HALL OF JUSTICE, LOS ANGELES,  
 and from the anatomic findings and pertinent history I ascribe the death to:

## EXSANGUINATION

DUE TO:

MULTIPLE STAB WOUNDS

(final 8/19/69)

## ANATOMIC SUMMARY

1. Stab wound of aorta.
2. Stab wound of left lung.
3. Gunshot wound of left lung.
4. Massive left hemopleura.
5. Multiple stab wounds of chest and back.
6. Contusion of left nose and eye.
7. Defense lacerations left hand.

## EXTERNAL EXAMINATION:

The unembalmed body is that of a normally developed, normally nourished white male which measures 66 and one-quarter inches in length and weighs 122 pounds. Rigor mortis is complete; post-mortem livor is posterior and dependent. Body heat is absent. The hair is black and is normal in amount and distribution. Inspection and palpation of the scalp reveals no evidence of injury. The external ears are unremarkable. There is a recent severe contusion involving the left periorbital region, the root bridge and tip of the nose and extending over into the upperlip. The irides are brown. The pupils are round and equal measuring 4 mm in diameter. There is ecchymosis in the left conjunctival area associated with the noted contusion. The teeth are the deceased's own and in good repair. There is a small amount of fresh blood within the mouth. The tongue is unremarkable. The neck is symmetrical and free from injury. The thorax and abdomen are symmetrical and contain numerous stab and gunshot wound which will be detailed below. The external genitalia are adult male. The penis is circumcised. Inspection of the back reveals numerous stab wounds which will be included in the description below. The extremities are normally developed and are unremarkable except for the injuries to be noted. There is a laceration of the back of the left hand measuring approximately 2 1/2 inches in length. This is superficial and probably constitutes a "defense" mark.

#69 8795  
JAY SEBRING  
AUGUST 10, 1969

2

### LISTING OF STAB WOUNDS

#### FATAL WOUND:

This is the fatal wound and is about 1 1/2 inches in length. It is almost exactly in the mid-line, 15 1/2 inches below the top of the head. This wound penetrates deeply into the thorax and results in severance of the artery to be described.

#### Stab wound #2:

This is a penetrating stab wound measuring 1 1/2 inches in length. It lies 16 3/4 inches below the top of the head and 1 3/4 inches to the left of the anterior mid-line.

#### Stab wound #3:

Stab wound #3 lies 12 1/2 inches below the top of the head and 4 inches to the left of the anterior mid-line. It is 1 1/2 inches in length and has a sharp edge and is directed toward the mid-line and a blunt edge, laterally, and upward.

#### Gunshot wound:

On the left chest just at the axillary fold 15 1/2 inches below the top of the head and 7 1/2 inches to the left of the anterior mid-line is the gunshot wound of entrance 1 1/4 inches in diameter. This shows a peripheral abrasion ring and is clearly an entrance wound.

At fluoroscopy bullet fragments are noted anteriorly about 3 inches below the gunshot entrance wound. These fragments are small and can be seen in the fluoroscope, but are not detectable and locatable on dissection.

#### Stab wound #4:

This is a penetrating stab wound 13 inches below the top of the head and at the mid-line. It is 1 1/2 inches in length and has a sharp edge directed toward the left.

#### Stab wound #5:

This is a penetrating stab wound 1 1/2 inches in length, 14 inches below the top of the head, 2 1/2 inches to the left of the posterior mid-line.

#### Stab wound #6:

This is a penetrating stab wound 18 inches below the top of the head and 1 3/4 inches to the left of the posterior mid-line. It measures about 1 1/2 inches in length and has a sharp edge directed toward the left. To the right of this is a recent contusion.

#69 8795  
JAY SEBRING  
AUGUST 10, 1969

3

#### INTERNAL EXAMINATION:

The body is opened by the usual Y-shaped incision. The subcutaneous fat is found to be normal in amount, color and distribution. The sternal plate is removed. The left pleural cavity contains an estimated 2500 cc of blood. The right contains only a very small amount of blood. There are no adhesions. The pericardial cavity is clear. The abdominal cavity contains a very small amount of blood.

#### HEART:

The heart weighs 340 grams and is symmetrical. It is opened along the course of the blood. The valve measurements are within normal limits. The valves are free of disease. The myocardium is dark red. There is no evidence of old or recent infarction. The coronary arteries are patent throughout.

#### LUNGS:

The right lung weighs 800 grams. The left approximately 300 grams and is completely collapsed by the surrounding blood. The pleural surfaces are smooth. The right lung shows marked congestion and edema, but no consolidation. There is marked evidence of aspiration of blood. The left lung is collapsed. There is severing of the left main pulmonary artery at its entrance into the hilum of the lung. This is the apparent continuation of stab wound #5. There are several other superficial stab wounds of the left lung.

#### AORTA:

The aorta arises normally from the heart. The right subclavian and common carotid arteries are unremarkable. The innominate artery is almost severed from its attachment to the arch of the aorta, the origin of the fatal hemorrhage and appears to be the continuation of stab wound #1.

#### NECK ORGANS:

The neck organs are dissected and removed. There is no evidence of injury. The hyoid bone is intact as are the laryngeal cartilages. The airway is patent.

#### LIVER:

The liver weighs 1200 grams. The capsule is smooth and transmits a dark reddish brown color. On section there is congestion, but no other remarkable change.

#69 8795  
JAY SEBRING  
AUGUST 10, 1969

SPLEEN:

The spleen weighs 150 grams. The capsule is somewhat tense. On section there is intense congestion.

PANCREAS:

Grossly unremarkable.

ADRENALS:

Bilaterally symmetrical; grossly unremarkable.

KIDNEYS:

The kidneys weigh 210 grams together. On section the capsules strip easily leaving a smooth surface. The architecture is well preserved and the cut surface is congested. The bladder contains only about one ounce of urine. The prostate is unremarkable to palpation.

GASTROINTESTINAL TRACT:

The GI tract is removed from esophagus to rectum. The esophagus is unremarkable. The stomach contains a fluid type meal in which particles are not identified. The meal remains in the stomach. The remainder of the GI tract is unremarkable.

MUSCULOSKELETAL SYSTEM:

The left 5th rib is fractured by a bullet track in the posterior axillary line. The sternum and ribs are penetrated by stab wounds.

HEAD:

The scalp is incised and reflected. There is no evidence of injury. The calvarium is removed by saw-cut and there is no fracture. The dura is intact. No epidural or subdural hematoma is noted. The brain weighs 1320 grams. There is congestion of the surface vessels. On serial section congestion and edema are noted which contain no petechiae. The pituitary lies in its normal place and is unremarkable.

*Russell C. Henry*  
RUSSELL C. HENRY, M. D.  
DEPUTY MEDICAL EXAMINER

RCH/ah/g  
8/21/69

DIRECTED AND SUPERVISED BY

*Thomas T. Noguchi*  
THOMAS T. NOGUCHI, M.D.  
Chief Medical Examiner-Coroner

COUNTY OF LOS ANGELES  
OFFICE OF CHIEF MEDICAL EXAMINER-CORONER

MEDICAL REPORT

Name JAY SEBRING Occupation Taxicab Driver Case No. 69-8795

Date 8/10/69 Time 2:15 PM IN  Crypt # 24 OUT  MORTUARY M.E. CORONER  
 INVESTIGATION  AUTOPSY  PENDING  FINAL DN 8/10/69 Dr. Henny

CAUSE OF DEATH: EXSANGUINATION

Due to: MULTIPLE STAB WOUNDS

RCH:p  
Final 8/19/69

- Micro.  Neuro
  - Bact.  Med. History
  - P.R.  S.P.R.
  - Photo By
  - X.RAY.  A.S.S
  - Toxicology
  - Alcohol  Over 24 Hrs.
  - Barbs.  C.O.
  - Other - Explain Below
- Amphetamines, Narcotics  
SPECIMENS SUBMITTED

OTHER SIGNIFICANT CONDITIONS CONTRIBUTING TO DEATH

- NATURAL  ACCIDENT  SUICIDE  HOMICIDE  UNDETERMINED

DATE OF OPERATION \_\_\_\_\_ OPERATION - CHECK ONE  
 OPERATION PERFORMED  FINDINGS USED IN DETERMINING ABOVE STATED CAUSE OF DEATH  OPERATION PERFORMED - FINDINGS NOT USED IN DETERMINING ABOVE STATED CAUSE OF DEATH

Evidence of Injury:  Yes  No At work  Yes  No SUICIDE NOTE  Yes  No FETAL DEATH CERTIFICATE

Embalmed by: Bodley License No. 4753 Blood Sample Taken  Yes  No Explain \_\_\_\_\_

Rx No. none Date Filled: \_\_\_\_\_ Contents: \_\_\_\_\_ Amount Prescribed: \_\_\_\_\_ Amount Remaining: \_\_\_\_\_

PHYSICAL DESCRIPTION Age 26? Sex M Race CAU Complexion MED Wt. 122 lbs. Ht. 66 1/2 in.

Hair BLACK Teeth Lower Eyes Blue Pupils NR Scars, amputations, LRO SCAR ARMEN

Appliances on body CARD AROUND NECK Tattoo or deformity NONE

Hospitalized  Yes  No Hospital Report  Yes  No Hospital No. \_\_\_\_\_ Unit \_\_\_\_\_

In A HOUSE Jail \_\_\_\_\_ Hospital Duration \_\_\_\_\_

For APP ASSAULT

Physician \_\_\_\_\_ Address: \_\_\_\_\_ Phone: \_\_\_\_\_

Diagnosis or Comment: \_\_\_\_\_

Information taken by M. H. Johnson

MEDICAL EXAMINER'S COMMENTS:  
Multiple stab wounds of chest + back  
Stab wound of innominate artery  
GSW left chest  
Massive exsanguination  
Massive left hemothorax

R.C. Henny, M.D.

CERTIFICATE ISSUED TO MORTUARY Pending  By \_\_\_\_\_ FINAL  By \_\_\_\_\_

CERTIFICATE MADE Pending  By \_\_\_\_\_ INQUEST  By \_\_\_\_\_ FINAL  By P

COUNTY OF LOS ANGELES  
DEPARTMENT OF CHIEF MEDICAL EXAMINER-CORONER  
PRELIMINARY EXAMINATION REPORT

Name JAY SEBRING Case No. 19-87-15

RIGOR MORTIS:

NECK:

Anterior flexion 4+  
Posterior flexion 4+  
Right lateral flexion 4+  
Left lateral flexion 4+

JAW: 4+ HIP: 4+  
SHOULDER: \_\_\_\_\_ KNEE: 4+  
ELBOW: \_\_\_\_\_ ANKLE: 4+  
WRIST: \_\_\_\_\_

(LT) SHOULDER (4+)  
(RT) SHOULDER (2+)  
(RT) ELBOW (2+)  
(LT) ELBOW (4+)

TEMPERATURE:

ENVIRONMENT TEMPERATURE 74° F

DATE 8-9-69 TIME 6:2 (AM/PM)

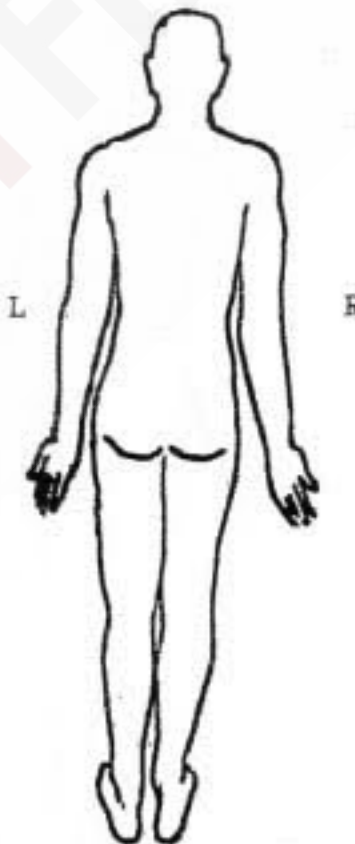
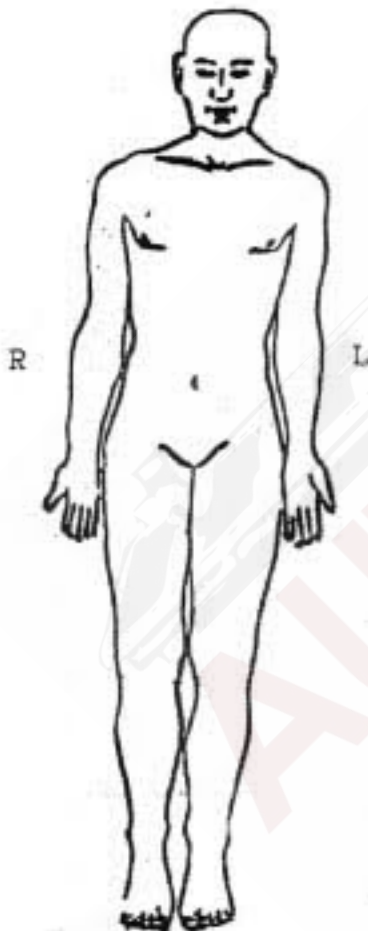
LIVER TEMPERATURE = 82.5° F

WHERE TAKEN OFFICE

DATE 8-9-69 TIME 6:14 (AM/PM)

LIVOR MORTIS:

Use shading on diagrams to illustrate location.  
Describe intensity of coloration. (use scale)  
Permanent or blanches under pressure? Describe.



SCALE

4+ = Extreme Degree  
3+  
2+  
1+  
0 = Absence/Negative

Remarks: Body fully clothed

J. Guinaghe  
Coroner's Investigator

Date 8-9-69 Time 6:16 (AM/PM)

COUNTY OF LOS ANGELES  
DEPARTMENT OF CHIEF MEDICAL EXAMINER-CORONER  
PRELIMINARY EXAMINATION REPORT

Name Jay Sebring Case No. 69-8745

RIGOR MORTIS:

NECK:

Anterior flexion 0  
Posterior flexion 0  
Right lateral flexion 0  
Left lateral flexion 0

JAW: 4+ HIP: 3+  
SHOULDER: 2+ KNEE: 3+  
ELBOW: 2+ ANKLE: 3+  
WRIST: 3+

TEMPERATURE:

ENVIRONMENT TEMPERATURE - 75° P

DATE 8-9-69 TIME 8:45 AM  
PM

LIVER TEMPERATURE = 82° F

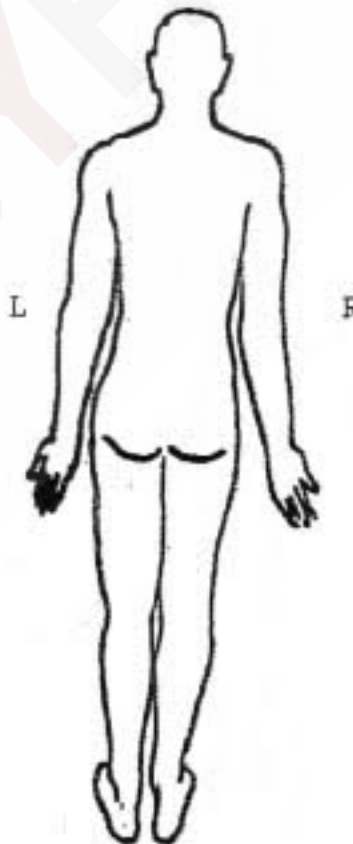
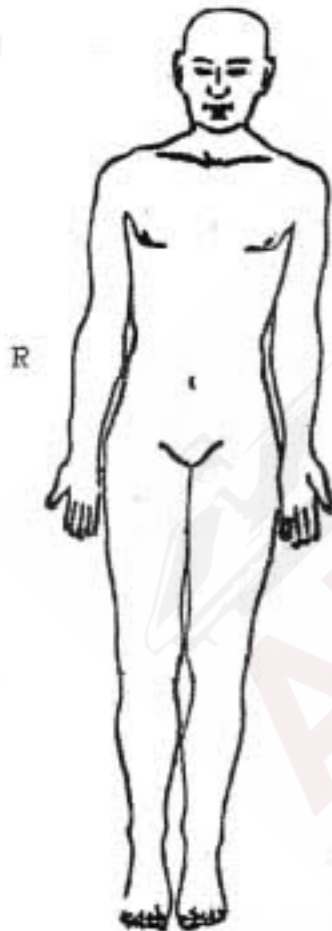
WHERE TAKEN (OFFICE)  
IN CRYPT 5 MINUTES

DATE 8-9-69 TIME 8:43 AM  
PM

(LT) SHOULDER (4+)  
(RT) SHOULDER (2+)

LIVOR MORTIS:

Use shading on diagrams to illustrate location.  
Describe intensity of coloration. (use scale)  
Permanent or blanches under pressure? Describe.



SCALE

4+ = Extreme Degree  
3+  
2+  
1+  
0 = Absence/Negative

Remarks:

Callaghan  
Coroner's Investigator

Date 8-9-69 Time 8:45 AM  
PM



COUNTY OF LOS ANGELES  
 DEPARTMENT OF CHIEF MEDICAL EXAMINER-CORONER  
 PRELIMINARY EXAMINATION REPORT *(L) first piece*

Name Dr. Jay Sebring Case No. 69-879.5

**RIGOR MORTIS:**

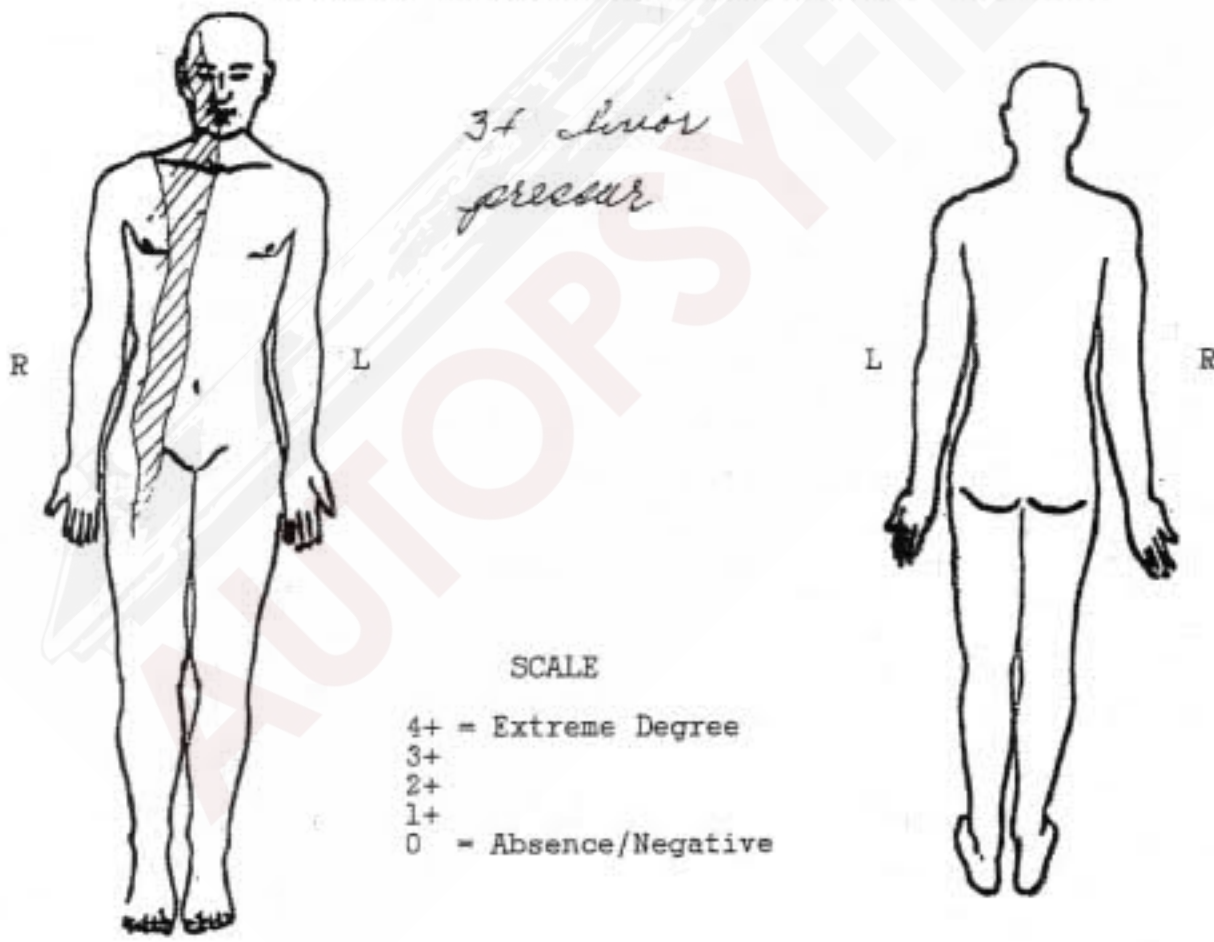
NECK:  
 Anterior flexion 4+  
 Posterior flexion 4+  
 Right lateral flexion 4+  
 Left lateral flexion 4+

JAW: 4+ HIP: 4+  
 SHOULDER: 4+ KNEE: 4+  
 ELBOW: 4+ ANKLE: 4+  
 WRIST: 4+

**TEMPERATURE:**  
 ENVIRONMENT TEMPERATURE 83 F  
 DATE 8 9 TIME 2:00 PM  
 LIVER TEMPERATURE = 83° F  
 WHERE TAKEN Scene  
 DATE 8 9-69 TIME 3:10 PM  
 Rectal 3:30 78°

**LIVOR MORTIS:**

Use shading on diagrams to illustrate location.  
 Describe intensity of coloration. (use scale)  
 Permanent or blanches under pressure? Describe.



Remarks:

Coroner's Investigator \_\_\_\_\_ Date \_\_\_\_\_ Time \_\_\_\_\_ AM PM

COUNTY OF LOS ANGELES  
OFFICE OF CHIEF MEDICAL EXAMINER-CORONER  
MEDICAL REPORT

Case No. 69-8792

Date: 8-9-69

Dr. \_\_\_\_\_

CONTINUATION SHEET

apparently entertaining a mixed group of 4-5  
young people at Jim Linn Insurance, 2nd and Grand  
St. - Suite Type Home. The party was broken  
up by police about the street and nearby during  
the afternoon into early evening 8-9-69.

At about 12:30 am 8-9-69 a nearby neighbor re-  
ported later to heard a sound of shot echo about  
1/2 mile. Approximately 9:00 am 8-9-69 house held mad  
search for body to find a scene of apparent car  
crash. House doors opened + some light got on  
substance ajar. An inscription in blood upon  
front door. One apparently dead body located in  
driveway east of late model Rambler Van located  
parked in parking area at entrance gate (John Doe 85)

Another apparently dead body (69-8793) crumpled to  
ground in front of veranda. Body dressed casually  
for occasion (A/S). The third apparently dead  
body on lawn about 60 feet south of (69-8793) lying  
on back and dressed apparently for sleep. This labeled  
case # 69-8794. (A/S)

Two bodies - a man (69-8795) and woman -  
deceased were found in living room in front  
of east fire place at foot of large sofa. Bodies  
on floor. Man in casual party dress and decollet  
in bra and briefs (A/S). A long possibly 1/4 inch  
nylon cord was looped about each of these persons  
necks and also looped over a supporting beam  
of ceiling loft over head. A belt looped apparently  
around neck of man prior to looping of rope.

A caretaker - occupying small house at end of  
large lot and somewhat away from house had  
entertained a young man earlier in evening to  
about 12:30 a.m. 8-9-69. when this man was  
gone. The John Doe 85 in auto. This possibly was  
seen by some young men. The caretaker with ques-  
tioned by police appeared unaware of apparent  
fact that premises at time happened. Unknown

- continued

COUNTY OF LOS ANGELES  
OFFICE OF CHIEF MEDICAL EXAMINER-CORONER

MEDICAL REPORT

Case No: 44-5746

Dr. \_\_\_\_\_

CONTINUATION SHEET

... of struggle appeared localized in  
... of living room where disorient and  
... since victim was sitting and  
... on floor. Found an .38  
... on area of about 2'x2'  
... small amount blood in open garage  
... also a small amount in  
... on back steps leading to  
... pool at rear of house and adjacent  
to driveway (69-3794)

No weapons nor suspects in custody.  
Local homicide witnessing autopsy

Inken

OBTAIN BLOOD AT AUTOPSY  
JG

SEBRING - FATHER  
BENARD J. KUMMER  
16626 STANSBURY  
DETROIT, MICHIGAN

76AB78- Cdb 1-69

COUNTY OF LOS ANGELES

OFFICE OF CHIEF MEDICAL EXAMINER-CORONER

AUTOPSY CHECK SHEET

Name Jay Sebring

File # 69-8795 Date 8/10/69 Time 2:15 PM

EXTERNAL EXAM

Sex M  
 Race W  
 Age 26?  
 Height 66 1/4"  
 Weight 122  
 Hair Black  
 Eyes Br. 4mm  
 Sclera Clear  
 Teeth own  
 Mouth little blood  
 Tongue  
 Nose contusion at root,  
 Chest " left eye  
 Breasts " tip of nose upper lip  
 Abdomen Stab + GSW's  
 Scar see chts  
 Genital OK circum  
 Edema  
 Skin  
 Decub  
 HEART Wt 340  
 Pericard  
 Hypert  
 Dilat  
 Muscle  
 Valves  
 Coronar  
 AORTA stab at root inorninate  
 VESSELS almost comp. severance  
 LUNGS Wt  
 R 800  
 L 300 collapsed  
 Adhes stab wound left,  
 Fluid main art.  
 Atelectasis GSW lower lobe  
 Oedema  
 Congest 4+ 2500 cc  
 Consol  
 Bronchi  
 Nodes  
 HARYNX  
 RACHEA  
 HYROID  
 HYMUS

PERITONEUM

Fluid  
 Adhes  
 LIVER Wt 1200  
 Caps  
 Lobul  
 Fibros OK  
 G B  
 Calc  
 Bile ducts  
 SPLEEN Wt 150  
 Color  
 Consist OK  
 Caps  
 Malpig  
 PANCREAS  
 ADRENALS  
 KIDNEYS Wt 210 Y  
 Caps  
 Cortex  
 Vessels Neg  
 Pelvis  
 Ureter  
 BLADDER  
 GENITALIA 510g  
 Prost  
 Testes  
 Uterus OK  
 Tubes  
 Ovar

OESOPHAGUS  
 STOMACH fluid meal  
 DUOD & SM INT  
 APPENDIX  
 LARGE INT  
 ABDOM NODES  
 SKELETON  
 Spine  
 Marrow

L 5 rib off by ballist PAL  
sternum + ribs  
protected by slabs

BRAIN Wt 1320

Dura  
 Fluid  
 Ventric CE  
 Vessels  
 Ears  
 Nasal Sin  
 PITUITARY

TOXICOLOGY

Yes

SECTIONS

No

GROSS IMPRESSION

1. Stab wound aorta
2. " " lt. lung.
3. GSW left lung
4. massive left hemothorax
5. Multiple stab wounds of chest + back
6. Contusion nose + eye
7. "Deferens" lac. left ha

R. L. Harrison  
 Deputy Medical Examiner

69-8795

NAME: JAY SEBRING

DOCUMENTED WOUNDS	STAB	GSW	I cuts	Severe Contusions
Chest	3	1		
Back	4			
Hand - left (back)			1	
Face				X
TOTAL DOCUMENTED	7	1	1	X

SUMMARY OF WOUNDS:           7 stab wounds  
   1 gunshot wound  
   Incised cut  
FATAL WOUNDS:                 Severe contusions to facial area

WOUNDS NOT DOCUMENTED:    none, with explanation below.\*

- \* Stab Wound #7 - is diagrammed but not described on autopsy protocol.  
 Description: Measures approximately 1/2" in skin length and is located 9" below the top of head and 3" to left of midline, and lies in a horizontal position; the wound appears superficial.

T6R290A-Tox 4- 08 11-68

**REPORT OF CHEMICAL ANALYSIS**  
**LOS ANGELES COUNTY MEDICAL EXAMINER-CORONER**  
**Toxicology Laboratory**  
**Hall of Justice**  
**Los Angeles, California**

File No. 69-8795

Name of Deceased Jay Sebring Lab No. 8-145-69

Date Submitted August 7, 1969 Time 8 A.M.

Autopsy Surgeon R. Henry, M.D.

Material Submitted:

Blood <input checked="" type="checkbox"/>	Liver	Stomach
Brain	Lung	Lavage
Femur	Spleen	Urine
Kidney	Sternum	Gall bladder
Drugs	Chemicals	

Test Desired: Poisons

Laboratory Findings:

1. Blood: Ethanol, Barbiturates, Doriden, Meprobamate, Phenacetin, Quaalude and Soma absent
  2. Urine: Amphetamine absent
- Bile: Codeine and Morphine absent

Examined By 1. Lawrence Plutchak ~~Head~~ Toxicologist. Date August 13, 1969

J. Park  
2. J. Park

Toxicologist

August 13, 1969

REPORT OF MICROBIOLOGICAL ANALYSIS  
CHIEF MEDICAL EXAMINER-CORONER'S OFFICE  
Bacteriology Laboratory  
Hall of Justice  
Los Angeles, California

File No. 69-8795

Name of Deceased Jay Sebring

Date Submitted 8/10/69

Autopsy Surgeon T. Noguchi, M.D.

Material Submitted Blood for ABO and Rh typing.

Laboratory Findings:

BLOOD: Group O Rh negative.

Examined By

Robert J. Luke

Date

8/25/69

Jay Sebring                      Autopsy 8-10-69    at about 2:15 p.m.  
 P8779                              Supervised and directed autopsy performed  
    by Dr. R. C. Henry

Cause of death:    Exsanguination due to multiple stab wounds.

"exsanguination is a medical term designating conditions which, perhaps if I use the words, the term is "bled to death" - might be the term.

Identification of photographs, taken under your direction, on August 10, 1969, prior to the autopsy.

At scene:    Did you see Jay Sebring's body?    Yes.    In proximity of Miss Tate's body, in living room of residence; a rope around neck at time; rope around Mr. Sebring's neck extended to S. Tate's neck?    Yes.  
 (Finken cut rope at scene to separate bodies?    Yes)  
 Rope still around neck on arrival at coroner's office.

At H/J        Did you remove rope?    Yes, I did.    Turned over to a representative from LAPD.

How many stab wounds?                      7 stab wounds.

Original autopsy report indicated 6?        Yes.

You found an additional stab wound?        Yes.

How many fatal in and of themselves?    At least 3 would be fatal.

All 7 penetration wounds?                      Yes.

Any gunshot wound?    Yes.    1 gunshot wound.

Was gunshot wound fatal wound?              Yes, it could be classified as a fatal wound.

Original autopsy did not indicate that particular gunshot wound was a fatal wound?    That is true.

You re-evaluated and feel it could have been the fatal wound?

Yes.    To clarify:    The term "fatal wound" - it could be fatal -- that would be a division of the severeness of the wound, the injury to the body. Naturally, when injury is extensive, there are multiple stab wounds involved, one would be most fatal and other stab wounds could be fatal by itself if no medical attention is given. But in light of additional stab wounds, by separating which one is the fatal one, we often find difficulty, and we use the term, "could be fatal", and this is a category that you might also use the words, "potentially fatal"/

Diagrams.



Indicate on diagram the location of each wound, the part of the body penetrated, if fatal and why, and the direction of the thrust of each wound. Also the wound tract on the bullet wound.

- #1 Side of the mid-chest -- on the left side of the mid-chest. Fatal Measures 1 1/2 skin surface, penetrated front to back, and left to right, in an upper direction; ~~penetrated~~ severed a portion of the aorta, causing massive. Fatal
- #2 located slightly below location of #1, still in the chest, the mid-portion of the chest, slightly to the left side; measures 1 1/2 inches skin length, penetrating into the chest cavity.
- #3 Located on left side of upper chest, penetrating into the chest cavity.
- GSW: Found in the left axilla, inside the armpit, slightly in front of the midline of the left side of the chest; wound tract penetrated downward, penetrated to the left fifth rib, and through the left lung. Bullet was found adjacent to the exit wound, found in the back, basically the left side of the mid-back. "I personally recovered during fluoroscopic x-ray under fluoroscopic examination I found what appears to be fragments of lead which still remained in the bony structure which we did not attempt to pick up."

But you recovered part of the bullet? Yes. Near the exit wound Bullet had penetrated the body but did not penetrate through his garment, shirt, so the bullet was trapped in between the surface of the skin and the shirts. I might say that the gunshot wound did not disclose any powder residue or powder deposit on the surface of the entrance area. Significance: if muzzle distance is close, there are powder burns around the gunshot wound? Yes. You found no such powder burns? True.

Stab wound in mid-back,; measures 1 1/2 inches skin length.

- #5 *FATAL* Left side of mid-back; measures 1 1/2 inches skin length.
- #6 *FATAL* Lower portion of left mid-back; measures 1 1/2 skin length, and is one of three stab wounds penetrating into the lung, which if not immediately fatal, is potentially fatal. Fatal.
- #7 Left shoulder, measures 1/2 inch skin length; superficial.

Additional: Wounds found in back of the left hand, precisely between ring finger and middle finger of left hand; slicing type

Series of contusions -- on face -- tissue damage caused by a blunt force, dark, red, swollen soft tissues. This contused area found on nose, left upper and lower eyelids, and also lip, showing considerable swelling Caused by application of blunt force against facial structure, causing breakage of capillaries underneath the skin, called subcutaneous tissue, causing hemorrhage into tissues, causing swelling. Could be delivered by a number of objects but without obvious breaking of skin would exclude probability of sharp object such as axe or hammer, more likely the soft padded -- a heavy object capable of delivering blunt force. (most common usually a fist

P. 8794. Going back to powder burns and the absence thereof, how close does muzzle of weapon have to be before it will leave powder burns?

Varies quite a bit because:

where a person exposing the skin without having any clothing on;

If muzzle is close to skin, contacting the skin, the almost entire burnt and unburnt powder is propelled right into the tissue, which causes sometimes a tearing of the skin showing a singeing of hair and a large amount of deposit of the powder in the subcutaneous tissue; sometimes it goes deeper into the bony structures. It may show unburnt powder.

If muzzle distance is greater, then such unburnt powder may not be detectable in the wound tract, but on the surface. These are the grayish, dark grayish, round particles, deposits on the surface. Depending on weapon and cartridge, varies a great deal. In fact, very difficult to determine the muzzle distance unless the suspected weapon is tested.

Generally speaking, powder usually visible within 15 inches that is muzzle distance from skin is 15 inches, by careful examination we will see either unburnt powder or black smoke on surface of skin. Beyond that level, not detectable by naked eye, but often we can perform a chemical analysis.

Re Jay Sebring: Muzzle in excess of 15 inches from body? Yes.

#### MORNING RECESS

Identification of damaged bullet? First seen 8-10-69 during the examination; at the time of the fluoroscopy examination? Yes.

Mr. Sebring still had shirt on? Yes.

Looking through fluoroscopy, you saw this bullet? Yes. You removed bullet? Yes.

Placed in envelope for evidence and turned over to Mr. Lee (Sgt. Lee) of LAPD Crime Lab.

There was an exit wound? Yes. In the vicinity of his back. Was this bullet close to the exit wound? Yes - within two or three inches from the exit wound.

Bullet is damaged? Yes. The base, and also one side of the bullet is flattened.

Parts of the bullet no longer attached to the bullet? Yes.

Parts of the bullet have fallen off? Yes.

In the fluoroscopy examination did you find any bullet fragments? Yes, I did; in the back, in the center portion of the ~~body~~ body structure. I would think that the fragments were lodged in the spinal processes -- that is a portion of the spine. Did you remove these fragments? No. I did not attempt to do so.

COUNTY OF LOS ANGELES

OFFICE OF CHIEF MEDICAL EXAMINER-CORONER  
BODY FULL LENGTH ANTERIOR

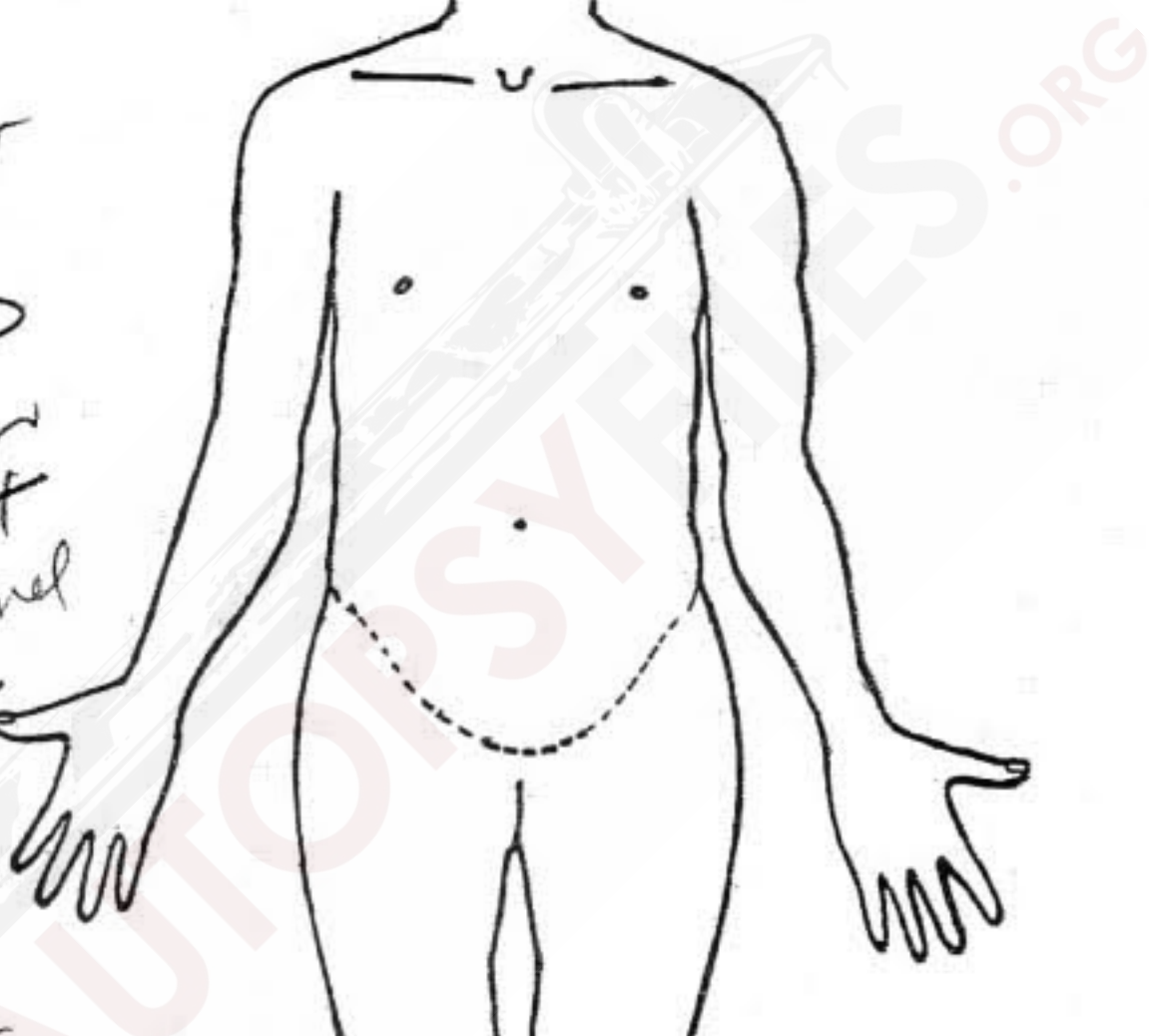
NAME Jay Sebring

Date \_\_\_\_\_

File # 69-8793

A BULLET  
FOUND  
under  
shirt  
R at the level  
of right  
iliac  
area

9:50  
AM  
Aug 10 1969  
H. T. T. R.



6

*Walter B. Meyer*  
M.D.  
County Medical Examiner.

COUNTY OF LOS ANGELES

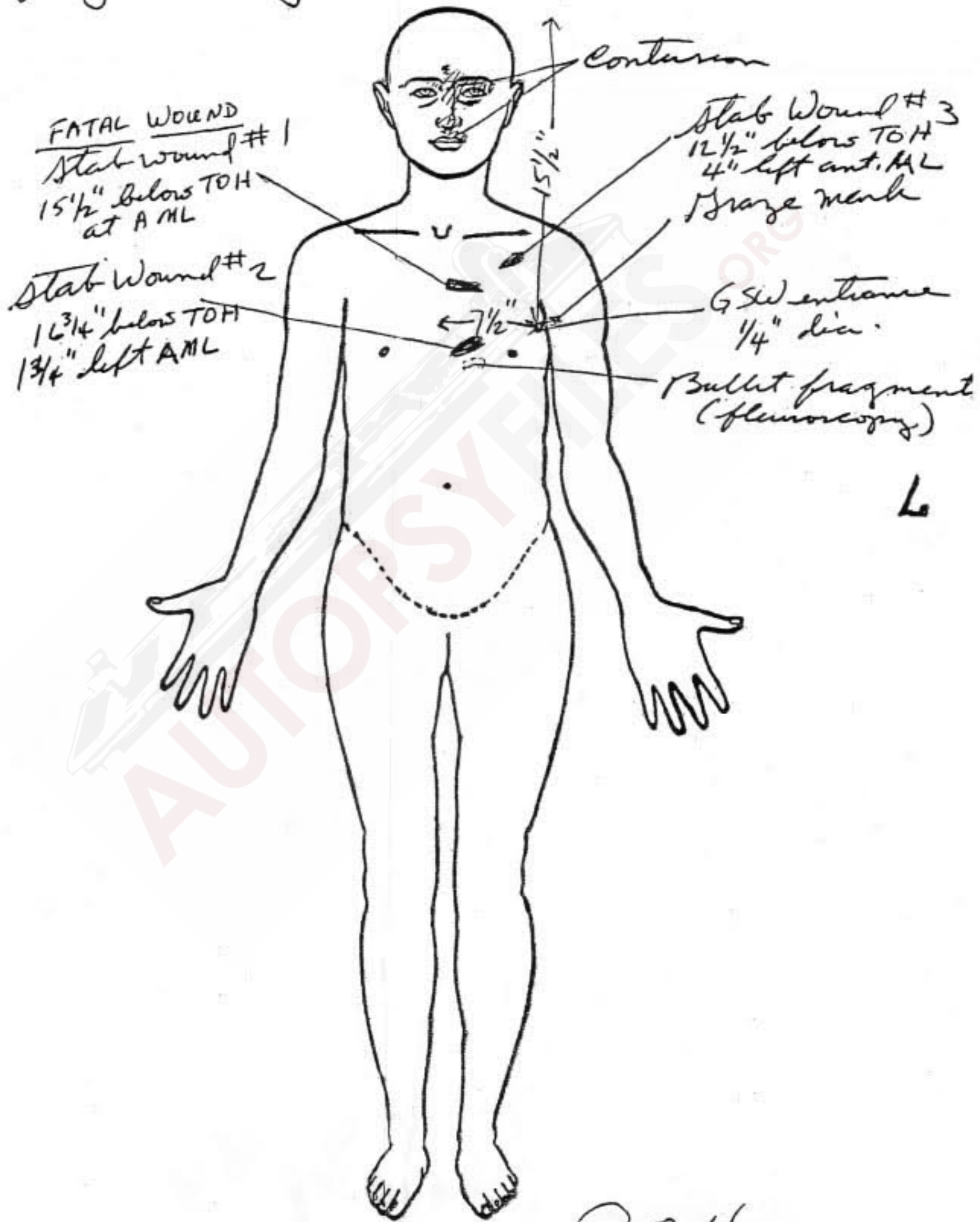
OFFICE OF CHIEF MEDICAL EXAMINER-CORONER

BODY FULL LENGTH ANTERIOR

NAME Jay Sebring

Date 8/10/69

File # 69-8795



R

L

R.C. Henry M.D.  
Deputy Medical Examiner

COUNTY OF LOS ANGELES

OFFICE OF CHIEF MEDICAL EXAMINER-CORONER

BODY FULL LENGTH POSTERIOR

NAME

Jay Sebring

Date

~~69-8795~~  
8/10/69

File #

69-8795

Stab wound # 7  
9" below TD  
3" left PML

Stab wound # 5  
14" below TDH  
2 1/2" left PML

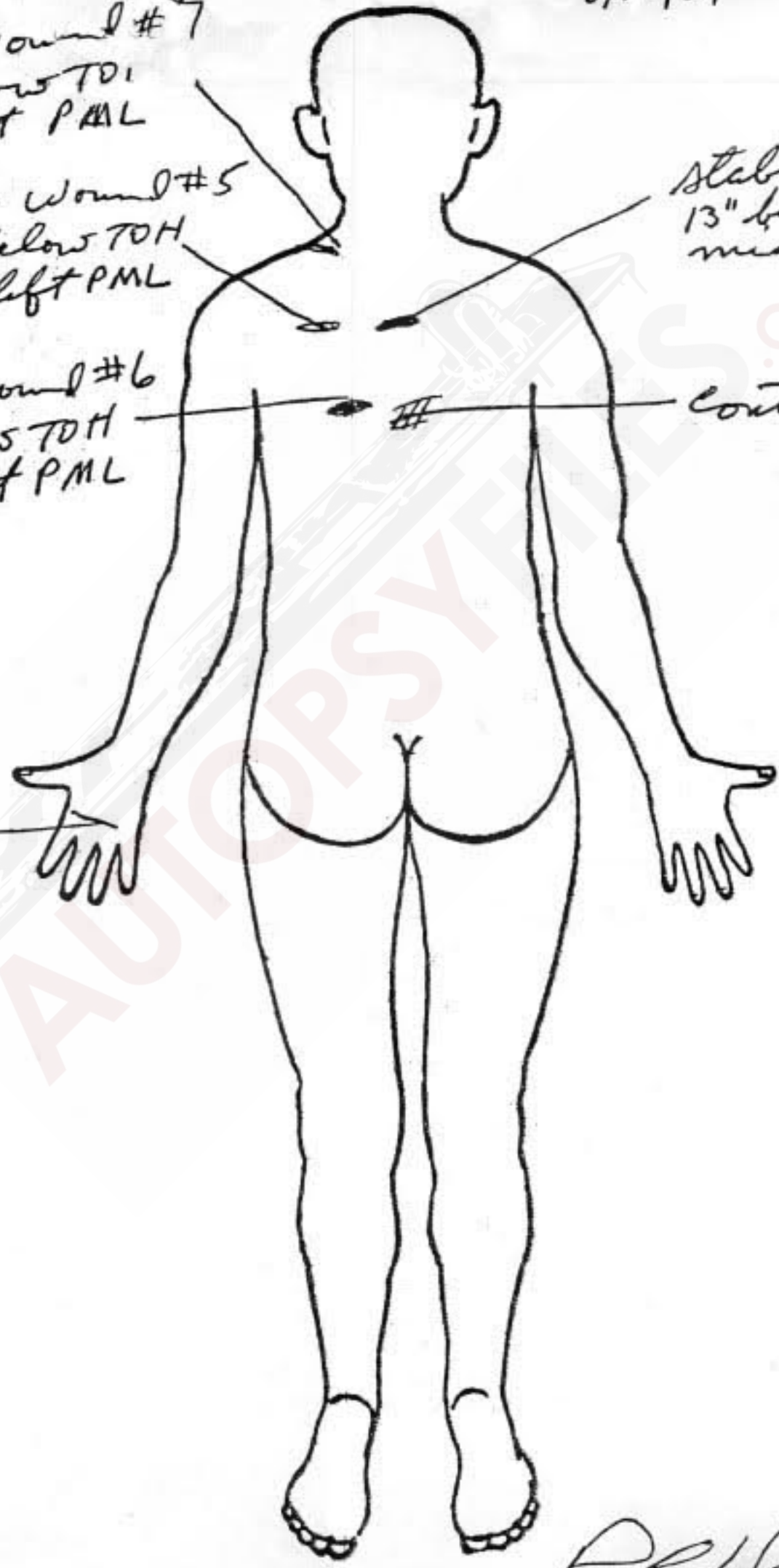
Stab wound # 6  
18" below TDH  
1 3/4" left PML

Stab wound # 4  
13" below TDH  
midline

contusion

L  
Laceration

R



R. C. Henry M.D.